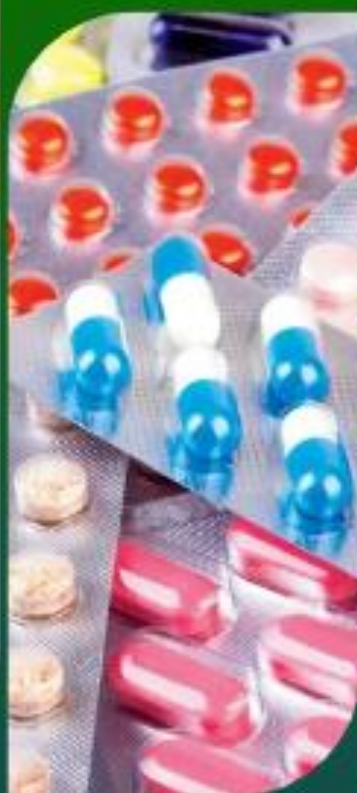
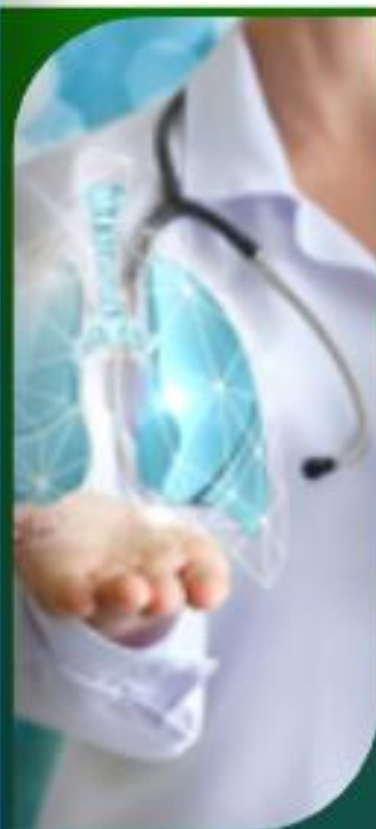
# **ORIENTAL JOURNAL OF MEDICINE AND NATURAL SCIENCES**

Open Access, Peer Reviewed Journal

Scientific Journal




- Medicine
- Pharmaceuticals
- Biology
- Chemistry
- Geology
- Agriculture



+998 33 0178868



[www.inno-world.uz](http://www.inno-world.uz)



## LIVER CHANGES AND ITS ROLE IN PREDICTING PREECLAMPSIA

Negmatullayeva Mastura Nurullayevna

2-Department of Obstetrics and Gynecology,  
Bukhara State Medical Institute, Bukhara, Uzbekistan

### ABSTRACT

This article considers the etiopathogenetic and clinical significance of increased intra-abdominal pressure, intra-abdominal hypertension (IAH) and cardiovascular maladaptation (CVD) in the development of preeclampsia. None of the existing theories fully explains the pathogenetic mechanisms leading to the development of preeclampsia. Preeclampsia is characterized by intra-abdominal compression of the kidneys, mesenteric and pelvic vessels, venous hyperemia and, as a result, ischemia of the kidneys, uterine-fetal-placental complex, liver, and pathological activation of the renin-angiotensin system. This article provides an insight into the role of intra-abdominal hypertension in the development of a complex of hemodynamic, respiratory and renal disorders that ultimately lead to preeclampsia and multiple organ failure in pregnant women. The article discusses the Doppler signs of intra-abdominal hypertension in the prognosis of preeclampsia, characterizes the qualitative and quantitative indicators of the Doppler wave patterns of the renal and hepatic vessels.

### KEY WORDS

Doppler, preeclampsia, liver blood flow.

### Relevance

Preeclampsia is a pathology of pregnancy that is one of the most severe complications for the mother and fetus and is characterized by severe dysfunctions of vital organs and systems [1,3,5,7].

The dynamic development of the gestational process leads to an increase in the load on the organ, exposes the liver to functional stress, but does not cause pronounced changes in it. At the same time, as pregnancy progresses, the reserve capacity of the liver is depleted [10,13,14]. With the development of PE, it is advisable to pay special attention to the functional state of the liver. It is the changes in the hepatobiliary system that are of leading importance in the pathogenesis of severe forms of preeclampsia [2,3,4,8,9].

Most of the parameters characterizing the functional state of the liver change even at the preclinical stage, thus making it possible to predict the development of liver failure [2,11,12]

The poor clinical picture of liver pathology observed in mild preeclampsia indicates the need to identify reliable laboratory criteria and assess the severity of its damage.

So far, the main criteria for the clinical diagnosis of hepatocellular insufficiency are the biochemical parameters of blood serum [6,7,8,9].

To assess the permeability of the plasma membrane and damage to hepatocytes, the level of enzymatic activity of the alanine aminotransferase-cytosolic enzyme of hepatocytes, as well as the enzymes of aspartate aminotransferase, alkaline transferase, lactate dehydrogenase, is used.

Based on a comprehensive study of morphological and functional changes in the state of the liver, one can get an idea of the changes in the hepatobiliary system in women with PE, which will allow solving some controversial issues, predicting its course and possible complications [3,6,7,9].

**Purpose of the study:** To study the systemic blood flow of the liver and its role in predicting preeclampsia.

**Materials and methods of research.** We studied 100 pregnant women with mild preeclampsia (group II), and 50 pregnant women with a physiological course of pregnancy, the control group (group I), 50 pregnant women with severe PE (group III). All observed patients underwent a complete clinical examination in a maternity hospital and a branch of the Republican Scientific Center for Emergency Emergency Care of the Bukhara region.

The age of the women of the studied groups were almost identical from 17 to 38 years old, the average age was  $22.3 \pm 2.1$  years. To conduct a clinical and static analysis and when examining pregnant women in the study group, we also took into account anamnestic data, concomitant extragenital and gynecological diseases, the onset and nature of the course of menstrual, sexual and reproductive function. Statistical analysis was carried out using the Fisher-Student and Pearson Statistics package. Written consents were obtained from all patients prior to the study. Women with chronic arterial hypertension and neurocirculatory dystonia were excluded from the groups of women studied.

An analysis of the age of onset of sexual activity showed the presence of an earlier sexual debut in patients with preeclampsia compared to women in the control group 17 (16-31) and 20 (18-24) years old, the average age of onset of sexual activity in the group with mild PE was 24 with individual fluctuations from 28 to 38 years old. We paid special attention to establishing the timing of PE, the time of its onset, the features of the course, the nature and effectiveness of therapy. All pregnant women underwent clinical and laboratory studies, including clinical and biochemical examinations.



Ultrasonic and Doppler study of liver blood flow was performed using a Sonoscape SSI 5000 diagnostic apparatus (China model) equipped with a convex transducer (3.5 MHz) equipped with a pulsating wave Doppler unit and a CFM function. The blood flow in the arteries and veins of the liver was studied (Pech A, Pech B, Thief B)

### Research results and discussion

Given that PE is based on generalized vascular spasm, arterial hypertension, and an increase in peripheral vascular resistance mainly due to arteriolospasm, it must be assumed that these changes in the homeostasis system clearly develop simultaneously with the development of PE at a time earlier than 28-32 weeks. Generalized vasospasm is not limited to changes in CG. It must be assumed that under its influence changes occur in the blood circulation of the uterus, liver and kidneys of the mother and the fetoplacental system, which cannot but affect the nature of the course of pregnancy and the development of the fetus. The table below shows Doppler values for renal, hepatic, and fetoplacental blood flow in pregnant women with mild PE. The data are shown in table 1.

**Table number 1. Indicators of organ and systemic blood flow in pregnant women with mild PE at 28-32 weeks' gestation,  $M \pm m$**

Organ and systemic circulation	Indicators	Control group (n=50)	Study group (n=100)	P
hepatic artery	SDO	2,35 $\pm$ 0,04	2,56 $\pm$ 0,02	<0,05
	IR	0,61 $\pm$ 0,03	0,72 $\pm$ 0,03	<0,05
hepatic vein	SDO	1,43 $\pm$ 0,03	1,45 $\pm$ 0,04	>0,05
	IR	0,40 $\pm$ 0,03	0,43 $\pm$ 0,02	>0,05
Portal vein	SDO	1,39 $\pm$ 0,04	1,41 $\pm$ 0,02	>0,05
	IR	0,36 $\pm$ 0,02	0,40 $\pm$ 0,02	>0,05

As can be seen from the table above, interesting, in our opinion, were changes in the hepatic artery in women with PE in whom changes in the hepatic artery in women with preeclampsia in whom LMS statistically significantly exceeded that in the control group by almost 9%, which and affected an equally significant increase in the IR of the hepatic artery relative to the control data by 18%. The blood flow in the hepatic and portal veins only outlined a tendency to some decrease in pregnant women with PE.

As for the ratio of hepatic arterial blood flow to that in the portal vein, according to our data, a statistically significant deterioration in arterial blood flow in the liver led only to a slight trend towards a decrease in blood flow in the hepatic and portal veins. The data are shown in table 2.

**Table number 2. Indicators of organ and systemic blood flow in women with severe PE in terms of gestation of 28-32 weeks**

Organ and systemic circulation	Indicators	I group (n=50)	II group (n=100)	III group (n=50)	P
hepatic artery	SDO	2,35±0,04	2,56±0,02	2,90±0,03	<0,05
	IR	0,61±0,03	0,72±0,03	0,91±0,04	<0,05
hepatic vein	SDO	1,43±0,03	1,45±0,04	1,39±0,03	>0,05
	IR	0,40±0,03	0,43±0,02	0,40±0,03	>0,05
Portal vein	SDO	1,39±0,04	1,41±0,02	1,38±0,04	>0,05
	IR	0,36±0,02	0,40±0,02	0,38±0,03	>0,05

From the data in the table, it is easy to see that with the progression of PE, vascular spasm continues to increase, covering mainly the arterial segment. LMS and IR in the hepatic artery, these values increased by 13.3 and 26.4, respectively, in severe PE.

### Conclusions

1. Summarizing the data obtained from instrumental studies of pregnant women with PE, we can note the following generalized vascular spasm, which mainly concerns the high-pressure circulatory system (resistive vessels), leads to a deterioration in blood flow in almost all organs and systems of the mother, including in the liver.
2. Thus, the study of the features of the arterial blood flow of the liver with the occurrence of hypertension during pregnancy can become a prognostic criterion for the development of PE and its progress with the transition to severe forms.

### BIBLIOGRAPHY:

1. Ashurova N. G., Rahmatullaeva M. M., Navruzova N. O. Rol' kol'poskopii v rannej diagnostike zabolevanij shejki matki // Al'manah molodoj nauki. – 2018. – №. 4. – S. 21-23.
2. Zaripova, D. YA., Negmatullaeva, M. N., Tuksanova, D. I., Ashurova, N. G. (2019). Vliyanie magnij deficitnogo sostoyaniya i disbalansa steroidnyh

- gormonov zhiznedeyatel'nosti organizma zhenshchiny. Tibbiyotda yangi kun, 3, 27.
- 3.Zaripova, D. YA., Negmatullaeva, M. N., Tuksanova, D. I., Ahmedov, F. K. (2019). Rol' Aleandronovoy kisloty (Ostalon) v lechenii perimenopauzal'nogo osteoporoza. Doktor ahborotnomasi, 4(3).
- 4.Manuhin I.B., Markova E.V., Markova L.I., Stryuk R.I. Kombinirovannaya nizkodozovaya antigipertenzivnaya terapiya u beremennyh s arterial'noj gipertoniej i gestozom // Kardiologiya. – 2012. – № 1. – S.32–38
- 4.Negmatullaeva M.N., Hamdamova, M.T, Hotamova M.T. (2022). Konservativnaya miomektomiya u zhenshchin reproduktivnogo vozrasta. ZHurnal vestnik vracha, 1(1), 62–64. <https://doi.org/10.38095/2181-466X-2020931-61-63>
- 5.Negmatullaeva, M.N., Dustova, N. K. (2012). Mochevaya kislota-marker razvitiya preeklampsii. Problemy biologii i mediciny, 1, 26.
- 6.Tuksanova D.I., Avakov V.E., Nazhmutdinova D.K., Negmatullaeva M.N., Ahmedov F.K. Osobennosti pochechnogo i pechenochnogo krovotoka u beremennyh s preeklampsiej. Rossijskij vestnik akushera-ginekologa. 2013;13(5):41-43.
- 7.Tuksanova, D. I., SHaripova, M. A. (2018). Osobennosti izmenenij pokazatelej sistemnogo i organnogo krovotoka u zhenshchin pri tyazhyolj preeklampsiej. Mezhdunarodnyj Kazahsko-Tureckij Universitet "Sovremennaya medicina tradicii i innovacii".–Kazakstan, 151-155.
- 8.Tuksanova, D. I. (2019). Osobennosti sostoyanie parametrov gomeostaza i kardiogemodinamiki u zhenshchin s fiziologicheskim techeniem beremennosti. Novyj den' v medicine-Tibbiyotda yangi kun-2019, 1(25), 159-163.
- 9.Tuksanova, D. I. (2019). Features of the state of parameters of homeostasis and cardiodynamics in women with the physiological course of pregnancy. Tibbietda yangi kun.-Tashkent, (1), 25.
- 10.Lam C., Lim K.-H., Karumanchi S.A. Circulating Angiogenic Factors in the Pathogenesis and Prediction of Preeclampsia. Hypertension. 2005;46:1077.
- 11.Chappell L.C., Shennan A.H. Assessment of proteinuria in pregnancy B.M.J., May 3, 2008; 336(7651): 968 969.
- 12.Myers J.E., Hart S., Armstrong S., Mires G.S., Beynon R., Simon J. Gaskell S.J., Baker P.N. Evidence for multiple circulating factors in preeclampsia. //Am. J. Obstet. Gynec. 2007. - 196 (3). - P. 266.
- 13.Sibai B.M. Biomarker for hypertension-preeclampsia: are we close yet?// Am.J.Obstet.Gynec.2007.-Vol.196.-№1.
- 14.Thangaratinam S., Coomarasamy A., Sharp S. et al. Tests for predicting complications of pre-eclampsia: a protocol for systematic reviews. B.M.C. Pregnancy Childbirth.-2008Aug11;8(1):38.



MUNDARIJA   TABLE OF CONTENTS   СОДЕРЖАНИЕ		
1.	<b>VISUAL TIZIM UCHUN QANDLI DIABET ASORATLARINI OLDINI OLISHDAGI FARMAKOLOGIK INNOVATSIYALAR: ZAMONAVIY YONDASHUVLARI.</b> <i>S.T. Juraeva</i>	4
2.	<b>АРТЕРИАЛЬНОЙ ГИПЕРТЕНЗИЯ И ХРОНОТЕРАПИЯ</b> <i>Адизова Д.Р</i>	9
3.	<b>СОВРЕМЕННЫЕ МЕТОДЫ ДИАГНОСТИКИ ПРЕЭКЛАМПСИИ</b> <i>Туксанова Дилбар Исматовна</i>	14
4.	<b>LIVER CHANGES AND ITS ROLE IN PREDICTING PREECLAMPSIA</b> <i>Negmatullayeva Mastura Nurullayevna</i>	22

INNOVATIVE  
WORLD

